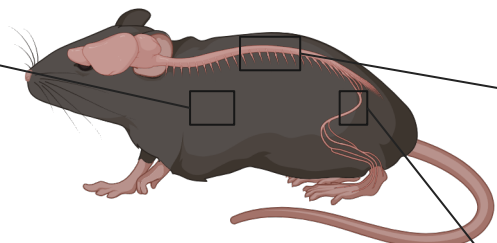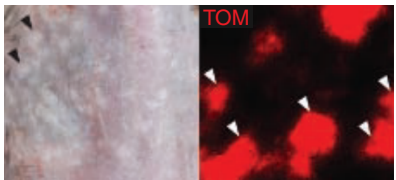

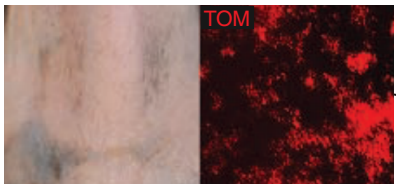
cutaneous neurofibromas

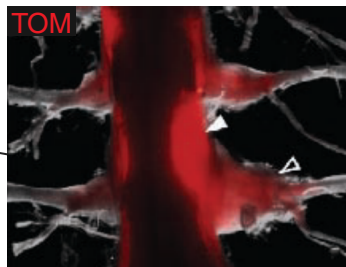
macroscopic view of the shaved back skin epifluorescent microscope



Prss56^{Cre,+}, *Rosa26*^{Tom,+}, *Nf1*^{fl/fl or -}

plexiform neurofibromas (pNFs)

paraspinal pNFs



subcutaneous pNFs

