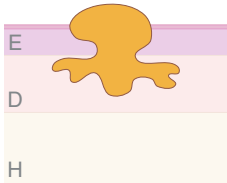


cutaneous NF

nerve endings

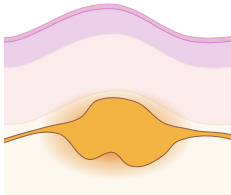


plexiform NF

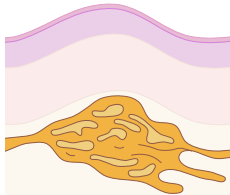
sub-cutaneous, along peripheral nerves

paraspinal, nerve roots

diffuse



"bag-of-worms"



nodular

